


ICSJS 2015

1st International Conference on Sacroiliac Joint Surgery

Sept. 18th - 19th 2015
Hamburg/Germany



ABSTRACTS +
PROGRAM

Conference language: ENGLISH

Surgeon Inspired. Superior Innovation.

IMAGINE

Your Patients Living Free of Pain
We are dedicated to making that happen

SI-DESIS[®]  **IMAGINE**
MIS Intraarticular Sacroiliac Joint Fixation and Fusion **Obtaining**
a True
Arthrodesis

Imagine your patients waking up every day, doing the things they love, or want or need to do without unbearable pain.

Surgeon Inspired.

Imagine a spine surgeon who suffered from the same pain after collegiate sports injuries leading to a keen appreciation for the associated disabilities and inspiring the motivation to develop treatment solutions.

Superior Innovation.

Imagine decades of research and diverse surgical experience treating dysfunctional Sacroiliac Joints enhancing the advancement of diagnostic and treatment solutions.

Realization.

Imagine SI-DESIS[®], a **minimally invasive**, innovative system designed to stabilize and fuse a painful Sacroiliac Joint.

- Specifically designed instruments to directly prepare the joint space in order to obtain a **true** arthrodesis
- An intraarticular, interference-fit implant with stabilizing keels and a large bone graft window designed to fit in the plane of the Sacroiliac Joint
- Allows for safe placement of transfixing Sacroiliac screws via an alignment guide
- Utilizes an access system to protect adjacent tissues during the procedure

A key element of the method utilizes an anatomic pathway which minimizes the chances of damaging soft tissue or critical neurovascular structures especially in comparison to traditional techniques.

SI-Dx[™]
 **IMAGINE**
Accurately
Diagnosing
SI Joint
Pain

PELFIX[™]
 **IMAGINE**
Obtaining
a Stable
Pelvic
Foundation

SI-MOTION[™]
 **IMAGINE**
Relieving
SI Joint Pain
While Preserving
Motion

si-technology.co

320 East Vine Drive, Suite 217 • Fort Collins, Colorado 80524 • T: +1 970.422.1212 • info@si-technology.co

The SI Logo, SI-TECHNOLOGY, SI-Dx, PELFIX, SI-MOTION, SI-DESIS and their respective icons are trademarks of JCBD, LLC and are used by permission. ©2015 SI-TECHNOLOGY, LLC. All rights reserved.

U.S. Patent Nos. 8,808,377 8,979,928 and 9,017,407; JP Patent No. 5710646; AU Patent No. 2011205597; SG Patent No. 182463; MX Patent No. 327506; pending U.S. and foreign patent applications.

Not CE-marked. Not Available for Sale.


SI-TECHNOLOGY[®]



WELCOME

We are proud to welcome you to the 1st International Conference on Sacroiliac Joint Surgical Treatment at the Dorint Hotel in the beautiful city of Hamburg. The SIJ topic is still underrepresented in the established medical orthopedic and spine societies. Far from being a single minded industrial meeting, the concept of our conference will focus on 'round table' discussions opened by key lectures of internationally acknowledged experts.

A prognosis expects even a case ratio of up to 20 % of all spinal surgeries within the next 5 years – numbers which do not correspond at all to our experience! Diagnosis, pathological variations, sensitive neurovascular structures, pain generators are areas to be explored, surgical hypes must be routed into healing.

After 6 years of surgical experience it became clear to the founding members of our association that different patients need differential diagnosis and treatment. Therefore all current techniques including non-surgical treatment must be discussed open minded beyond any commercial conflict of interest. To avoid failed diagnosis, failed treatment and last not least failed investments it should be a priority for all serious active SIJ players to participate in this CME rewarded conference.

Our new association struggled very hard to get this conference done, which - inspite of a low budget - offers a high level discussion.

I express my thanks to all the experts who present their talks , setting aside a demand for full travel compensation or fees. Although being aware of the critical attitude of the meeting towards too early and too many surgeries and the demand for clinical evidence, the companies who support the conference deserve a special thanks for their cooperation - without this it would not have happened.

The venue offers the advantage of very close distance to the airport and train station. No need to mention the well known touristic attractions of this metropole city of Hamburg.

We are sure that you will enjoy your time in Hamburg!



Dr. med. Volker Fuchs
President SIMEG e.V.

The Conference is awarded with 18 CME credits by the Medical Association (Ärztammer) Hamburg

FRIDAY, SEPT. 18TH

08:00 h - Registration

09:00 h – Session 1

1. 09:00 h - Success and failure of SIJ arthrodesis – Lessons from history regarding surgical approach to address the mechanics and forces of the painful SIJ (Stark)
Erfolge und Misserfolge der SIG-Arthrodesese – Lektionen der Vergangenheit
2. 09:30 h - National/international register of SIJ fusion – a challenge for physicians and the medical device industry! (Sobottke)
Nationales/internationales SIG-Fusionsregister – eine Herausforderung für Ärzte und Industrie!
3. 10:00 h - Update on anatomy and histology of the SIJ – what do we really know? (Egund)
Update Anatomie und Histologie SIG – was wissen wir wirklich?

10:30 h - 11:00 h Coffee Break

4. 11:00 h - Innervation of the SIJ – are we sure it's mainly from dorsal ? (Neuhuber)
Innervation des SIG – wirklich hauptsächlich dorsal?
5. 11:30 h - SIJ biomechanics – which studies are the most reliable ones (cadaver vs. in vivo vs. finite element models) - or are we all too different? (Böhme)
Biomechanik SIG – welchen Studien können wir mehr vertrauen (Kadaver vs. in vivo vs. finite Elemente Modell) - oder sind wir alle zu verschieden?
6. 12:00 h - Diagnostic imaging: X-ray, MRI, CT, Scintigraphy, SPECT-CT – What's the adequate individual choice? (Koga)
Bildgebende Diagnostik – Röntgen, MRT, CT, Szintigrafie, SPECT-CT – was hilft uns wann weiter?

12:30 h - Lunch-Workshops

Industrial sponsors present the latest SIJ-medical devices, clinical data and hands-on tutorial

14:00 h - Session 2

7. 14:00 h - SIJ Arthritis – an obliged group of patients to receive arthrodesis, even at times of biologicals? (Sieper)
SIG- Arthritis – ein dankbares Patientengut für eine Arthrodesese selbst zu Zeiten von Biologicals?
8. 14:30 h - Surgery or not? - How to clinically examine the SIJ? (Stuge)
OP ja oder nein? Welcher klinische Test gibt Antwort?
9. 15:00 h - Which SIJ injection is better to diagnose most SIJ-related pain correctly, intra-articular or peri-articular? What response do we require? (Kurosawa)
Welche SIG-Injektion eignet sich besser zur Diagnose des SIG-Schmerzes: intra- oder peri-artikulär? Welche Aussage fordern wir?

15:30 - 16:00 h Coffee Break

10. 16:00 h - Denervation – but do it right! (Roberts)
Denervieren – aber richtig!
11. 16:30 h - SIJ braces – what's the philosophy and do they really help? (Harms)
SIG-Orthesen was steckt dahinter und helfen sie wirklich?

17:00 h - Round-table:

12. Diagnostic algorithm for SIJ pathologies: can we establish a gold standard or shall we just continue to try what we are used to? (Fuchs, All)
Der Diagnose Algorithmus für SIG-Pathologien – wie könnte er aussehen – oder wollen wir alle so weiter machen wie bisher?

19:00 h - Conference Dinner in the restaurant EPPO

08:00 h – Session 3

13. 08:00 h - What are the different SIJ- and leg pain generators and what is the physicians' view on the appropriate therapy? (Donner)
Welche unterschiedlichen SZ-Generatoren am SIG gibt es, woher kommt der Beinschmerz und wie therapieren wir am besten aus ärztlicher Sicht?
14. 08:25 h - There's more than the SIJ: Considerations for when to operate on the sacroiliac joint(s) and the lumbar spine at the same setting (Eden)
Es ist nicht nur das SIG: Überlegungen zur einzeitigen Operation an SIG und LWS
15. 08:50 - Neurovascular Consequences and Comorbidities (Stark)
Neurovaskuläre Konsequenzen und Co-Morbiditäten
16. 09:15 h - It's not as simple as it seems: Complications of sacroiliac fusion and salvage considerations (Graham Smith)
Nicht so leicht, wie es aussieht: Komplikationen und Revisionsoptionen bei SIG-Arthrodesen

09:45 h - Coffee Break**10:00 h – Pro/Contra:**

17. SIJ arthrodesis – when and why do we use anterior, posterior or lateral techniques – or do 'many ways lead to Roma'? And what about preserving motion? (Chair: Murakami, Podium: Donner, Eden, Graham Smith, Kibsgård, Stark)
18. 11:00 h - Clinical studies on SIJ fusion – how true can we get? (Kibsgård)
Klinische Studien der SIG-Fusion - wie nahe kommen wir der Wahrheit?

11:30 h - Round-table (please download the preparing documents):

19. What preoperative data and scores do we need? How do we avoid comparing apples with pears in the future? (Kibsgård, Stuge, All)
Welche präoperativen Daten und Scores brauchen wir - oder wie können wir es verhindern in Zukunft Äpfeln mit Birnen zu vergleichen?
20. 12:00 h - What do we demand from a control group and how do we validate the quality? (Stuge)
Welche Forderungen stellen wir an eine konservative Kontrollgruppe und wie stellen wir deren Qualität sicher?

12:30 h – Take home message and end of Conference

Please participate actively in the discussion and make sure to download the provided conference papers from our website (*the link will be provided with the confirming email*).

- **Abstracts + Publications**
- **Clinical SIJ score proposals (discussed in topic 19)**

We also recommend the recently published related book 'Surgery for the painful, dysfunctional SIJ'

14:00 h – 15:00 h – EXTRA offer:

Hands on: Clinical examination of the SIJ (Stuge)

1. **Böhme, Jörg**, PD Dr. med. habil., Clinic for Orthopedic and Traumatologic Surgery, Spine Center, University Hospital, Leipzig, Germany (5)
Co-author: Ligamentous influence in pelvic load distribution; Description of the iliolumbar ligament for computer-assisted reconstruction; Novel insights into the sacroiliac joint ligaments.
2. **Donner, Jeff**, MD, Colorado Spine Institute, Loveland, Colorado, USA (13, 17)
Dr. Donner is a American Board of Orthopedic Surgeons & American Board of Spinal Surgery certified orthopedic spinal surgeon who has over 20 years experience diagnosing and surgically treating patients with SI joint pain and dysfunction and has presented scientific papers at multiple international meetings on SI joint related topics during his career including the outcomes of SI joint fusion surgeries. Dr Donner recently authored a chapter in the book, 'Surgery for the Painful, Dysfunctional Sacroiliac Joint', focusing on the minimally invasive, posterior inferior approach.
3. **Eden, Sonia V.**, MD, Borgess Brain and Spine Institute, , Kalamazoo, MI, USA (14)
Assistant Professor at Western Michigan School of Medicine, Neurosurgery, Co-author of the book 'Surgery for the Painful, Dysfunctional Sacroiliac Joint'.
4. **Egund, Niels**, MD, Consultant Professor, DMsc, Institute: Department of Radiology, Aarhus University Hospital (3)
Author: 'Prevalence of degenerative and spondyloarthritis-related MRI findings in the sacroiliac joints and spine in patients with persistent low back pain'
5. **Fuchs, Volker**, Dr. med. , Orthopedic Department, AMEOS Clinic St. Salvator, Halberstadt, Germany (12)
SIMEG President and founding member. Dr. Fuchs started to operate on the SIJ in 2010. He directed the first multicenter study including 200 patients.
6. **Graham Smith, Arnold**, MD, FRCS, FACS, Jacksonville, FL 32256 (16, 17)
Dr. Arnold Graham Smith studied Medicine at King's College, London University, UK, and later studied Orthopaedic Rehabilitation at Rancho Los Amigos, in Los Angeles where he worked with paraplegics and wheelchair people in the SCI unit. Interdisciplinary treatment philosophy has stayed with him ever since and he still relies on the expertise of a treatment team for the best outcomes. He is a member of the Board of Directors of the ABSS (American Board of Spine Surgery), where he was chairman of the examination committee. He believes that spine surgery is now so complex that it should only be performed by surgeons with special training. Just as orthopaedic and neurological surgeons require Board certification, so spine surgeons can now become Board Certified. Dr. Graham Smith is a member of the North American Spine Society and a Founder Member of ISIS.
7. **Harms, Jürgen**, Prof. Dr. med., Spinal Surgery, Ethianum Klinik, Heidelberg, Germany (11)
Prof. Dr. med. Jürgen Harms is an internationally renowned specialist in the field of spinal surgery. He has conducted more than 10,000 spinal surgeries and is thus one of the most experienced experts on the spine worldwide. He has prepared innovative surgical techniques in scoliosis surgery, tumor surgery, transoral surgery, transforaminal lumbar interbody fusion (TLIF) or the dorsal fixation of the atlantoaxial complex which are in the meantime being practiced throughout the world. This experience led him to advocate to avoid unnecessary surgery. Prof. Harms has published several articles about SIJ biomechanics and physical treatment.
8. **Kibsgård, Thomas**, VMD, Orthopedic Department, University Hospital, Oslo, Norway (17, 18)
Author: 'Pelvic joint fusions in patients with chronic pelvic girdle pain: a 23-year follow-up'. He will present a review on available studies on SIJ surgical treatment.
9. **Koga, Hiroaki**, MD, Department of Orthopedic surgery, Kikuno hospital, Kagoshima, Japan (6)
Executive Vice President, Kikuno Hospital, 1995 – 2000: Instructor of Department of Orthopedic Surgery, Kagoshima Graduate School of Medical and Dental Sciences; 2001 – 2013: Director of Orthopedic Surgery Imakiire General Hospital, Kagoshima Japan; 2005 – 2013: Clinical Assistant Professor of Department of Orthopedic Surgery, Kagoshima Graduate School of Medical and Dental Sciences, board member of the 'Japanese Sacroiliac Joint Research Group'
10. **Kurosawa, Daisuke**, MD, Department of Orthopedic surgery, Low back pain and Sacroiliac joint center, JCHO Hospital, Sendai, Japan (9)
Daisuke Kurosawa, M.D. 2004: Graduated from Yamagata University School of Medicine. 2009–Present: JCHO Sendai Hospital Dept. of Orthopaedic Surgery/ Low Back Pain and Sacroiliac Joint Center. Board member of the Japanese Sacroiliac Joint Research Association. License: Japanese Board of Orthopedic Surgery. Instructor of Japanese Medical Society of Arthrokinematic approach.
11. **Murakami, Eiichi**, MD, Department of Orthopedic surgery, Low back pain and Sacroiliac joint center, JCHO Hospital, Sendai, Japan (17)
1981: Graduated from Tohoku University School of Medicine. Chief of Low Back Pain and Sacroiliac Joint Center in JCHO Sendai Hospital. Representative Director of the Japanese Sacroiliac Joint Research Association
12. **Neuhofer, Winfried**, Prof. Dr. med. , Anatomic Institute, FAU, University of Erlangen-Nürnberg, Germany (4)
1983 - 1992: Senior lecturer, Anatomy Institute, Univ. of Zürich. 1989 „Habilitation“ (PhD) in Anatomy, Histology and Embryology, since April 1992 Professor of Anatomy and Chairman, University of Erlangen-Nürnberg, Germany. Membership in Editorial Boards: Histochemistry and Cell Biology; The Anatomical Record. Associate editor: 'Cells, Tissues, Organs'; 'Innervation of the sacroiliac joint of the human (1995, Z. Rheumatol.)
13. **Roberts, Shannon**, PhD candidate, Division of Anatomy, Dept. of Surgery, University Toronto, Canada (10)
Member of a collaborative research team that includes Physical Medicine and Rehabilitation physicians, Dr. Eldon Loh and Dr. Robert Burnham, and clinical anatomist, Dr. Anne Agur. She is currently investigating the innervation of the sacro-iliac joint and the relationships of the nerves to ultrasound landmarks. Based on this work, a novel ultrasound-guided radiofrequency ablation technique for the treatment of sacro-iliac joint complex pain was proposed.
14. **Sieper, Joachim**, Prof. Dr. med, Head of Rheumatology, Charité - University Hospital, Berlin, Germany (7)
Prof. Sieper published more than 70 papers on 'Spondyloarthritis' and 'Ankylosing Spondylitis'
15. **Sobottke, Rolf**, PD Dr. med., Head of Orthopedic Department, Medical Center, Würselen, Germany (2)
Vice director of the spinal surgery register (German Spine Society)
16. **Stark, John Gregory** , MD, Orthopedic Surgeon, Backpain Clinic, Minneapolis, MN, USA (1, 15, 17)
Dr. Stark is actively researching the sacroiliac joint anatomy and pathology since more than 20 years and pioneered sacroiliac joint fusion using a posterior midline approach. Bone healing, innervation of the SIJ, biomechanics and restoraton of the anatomy are his main concerns which led him to the development of his Distraction Interference Arthrodesis (NeuroSafe ArthroBridging techniques).
17. **Stuge, Britt**, Senior Researcher, Div. for Neuroscience and Musculoskeletal Medicine, University Hospital, Oslo, Norway (8,19, 20)
She has practised as a physiotherapist since 1982, completing an MSc in 2001 and a PhD in 2005. Britt has worked in clinical practice with women experiencing pregnancy-related pelvic girdle pain for nearly 20 years. Amongst other published works she is co-author of the European guidelines for the diagnosis and treatment of pelvic girdle pain (2008) having been a member of the European Commission group exploring the subject.



**You like the
program?**

**You want to stay
involved?**

**Why not become a
SIMEG member?**

<http://simeg-international.com/en/simeg-ev/membership/>

#1 - 09:00 h

Success and failure of SIJ arthrodesis – Lessons from history regarding surgical approach to address the mechanics and forces of the painful SIJ (Stark)

Stark, John Gregory, MD, Orthopedic Surgeon, Backpain Clinic, Minneapolis, MN, USA

Teaching Positions

Shriner's Hospital for Crippled Children 1981-1991
Minneapolis, Minnesota

Assistant Professor of Orthopaedics 2000 - Present
University of Minnesota

Academic Appointments

Clinical Instructor, University of Minnesota 1984-1994
Minneapolis, Minnesota

Assistant Professor of Orthopaedics 2000-Present
University of Minnesota

Sacroiliac joint research: Dr. Stark is actively researching the sacroiliac joint anatomy and pathology since more than 20 years. Bone healing, innervation of the SIJ, biomechanics and restoration of the anatomy are his main concerns which led him to the development of his Distraction Interference Arthrodesis (NeuroSafe ArthroBridging techniques). He has been teaching his experience worldwide to several hundred surgeons.

ABSTRACT: [History of the SIJ Treatment I; Mechanical and Skeletal Anatomy]

Title: Revisiting surgical treatment of the painful sacroiliac joint. Lessons from history regarding surgical approach to address the mechanics and forces of the painful SIJ.

After almost 100 years, the surgical community now recognizes that the SIJ is subject to the same painful degeneration as the other elements of the hip-spine axis. Though it is subject to all other orthopedic diseases, including osteopenia, sepsis and neoplasia, its unusual shape and deep presence within the wall of the pelvis separates it from common methods of diagnosis or traditional methods of surgical exposure.

The history of the surgical treatment of the painful SIJ dictates some principles for treatment, but fails to include technical advances of imaging, bone metabolism, or implant science. Maximizing outcomes demands a deep understanding of developmental deformity, postoperative change, and aging.

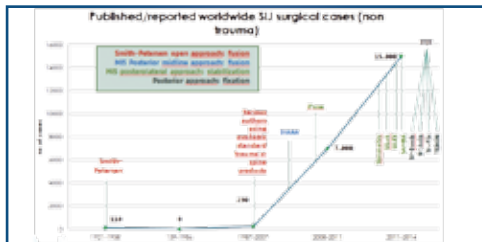
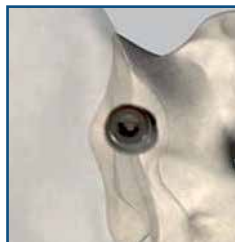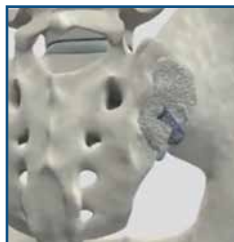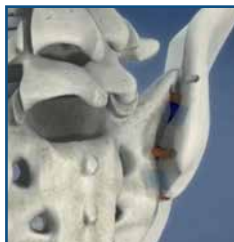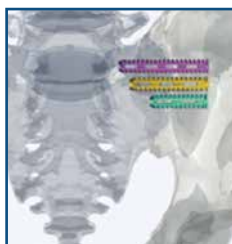
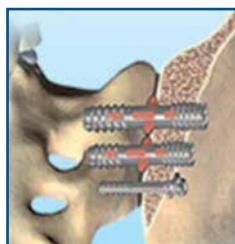
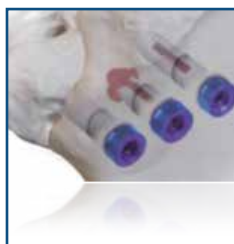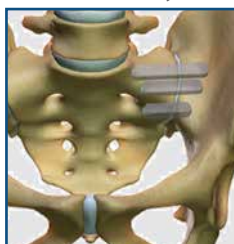#2 - 09:30 h

National/international register of SIJ fusion – a challenge for physicians and the medical device industry! (Sobottke)

Sobottke, Rolf, PD Dr. med., Head of Orthopedic Department, Medical Center, Würselen, Germany. Vice director of the spinal surgery register (German Spine Society)

(Editor's summary:) In the light of increasing discussion about necessary or unnecessary spinal interventions as well as about increasing number of surgical cases there is a superior demand for answers to the quality of indication and outcome. A register is able to provide these answers and has the advantage not to be a system directed by third parties.

SIJ-Fusion Systems



#3 - 10:30 h

Update on anatomy and histology of the SIJ – what do we really know? (Egund)

Egund, Niels, MD, Professor emeritus, DMSc. Clinical and scientific consultant, Dept. Radiology, Aarhus University Hospital, Denmark. Author: 'Prevalence of degenerative and spondyloarthritis-related MRI findings in the sacroiliac joints and spine in patients with persistent low back pain'

ABSTRACT:

The anatomy of joints provides an important basis for understanding the nature of pathologic lesions and their imaging appearances. This applies especially to the sacroiliac (SI) joints, which play a major role in the diagnosis of spondyloarthritis. They are composed of two anatomically different joint portions, a cartilage-covered portion ventrally and a ligamentous portion dorsally (Figure), the latter being a syndesmosis. The cartilaginous portion of the SI joints has previously been considered a synovial joint. However, the only available histological study of all parts of the joint has demonstrated that the proximal 2/3 anatomically is a symphysis (1, 2). Thus, the proximal 2/3 of the cartilaginous portion of the SI joint is not surrounded by a capsule, but held together by strong transverse ligaments ventrally and proximally. Dorsally, the cartilaginous joint space communicates directly with the syndesmosis (Figure).

In the distal 1/3 of the joint, the sacral side resembles a symphysis, but the iliac side have some characteristics of a synovial joint and is most distally surrounded by loose connective tissue with a faint synovial lining. The extraarticular aspects of the distal 1/3 of the cartilaginous joint are rich in vessels, especially dorsally in the adjacent ligamentous portion (1, 2).

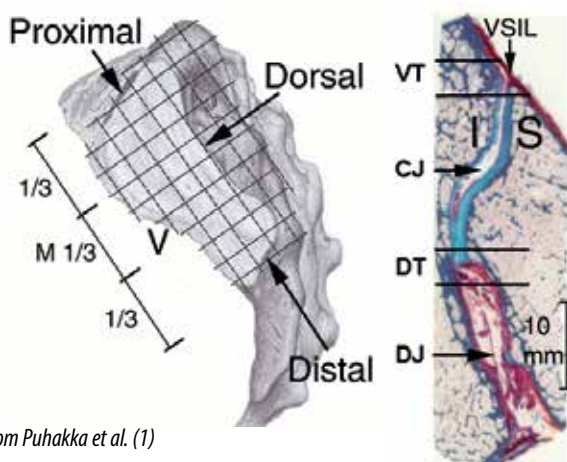
All imaging, being radiography, CT, ultrasound or MRI are based on interpretation of the normal and abnormal anatomy in two perpendicular planes. This is in specific true for the SI joint. The ventral and dorsal aspects of the cartilaginous joint can by MRI be assessed by oblique transaxial imaging only (Figure). In addition, oblique transaxial MR images with adequate sequences provides the opportunity to describe/report separately the sites of lesions within the cartilaginous and ligamentous portion of the SI joint. However, most MR studies in the literature and in daily clinical practice around the world (3) are based on oblique coronal slices only. In the literature, the ASAS recommendations (3) concerning synovitis, capsulitis and enthesitis (except proximally) have not been confirmed in two perpendicular planes by MRI. In our experience with routine use of transaxial fat suppressed sequences in all clinical and scientific examinations (e.g. 4, 5) since 1998 it may be impossible to separate synovitis from normal vascular structures (not assessed scientifically). Synovitis also appears rare in histological studies (6).

A number of anatomical variants may by MRI simulate inflammatory disease and may be related to symptoms. The nature of these can only be assessed by oblique transaxial MR images or CT.

Considering the anatomical composition of the sacroiliac joint and the most common sites of active inflammatory lesions as visualized by MRI, the target of SIJ injections guided by fluoroscopy and ultrasound may be questioned. Without a defined capsule dorsally, injections into the cartilaginous joint should not be possible.

Take home points

- ▶ The proximal 2/3 of the SI joint is a symphysis and thus without a capsule and synovia.
- ▶ The distal 1/3 has some characteristics of both a symphysis and a synovial joint.
- ▶ MRI in two perpendicular planes including an oblique fat saturated transaxial sequence is mandatory for accurate assessment and reporting of abnormalities. Contrast studies seems not to be necessary (7).
- ▶ Synovitis, capsulitis and enthesitis cannot be assessed by oblique coronal MR imaging only.
- ▶ Anatomical variants may give rise to symptoms and may simulate active inflammatory disease. A challenge for the future to investigate.



From Puhakka et al. (1)

Left: Definition of the four aspects of the SI-joint and the subdivision in proximal/distal thirds. The perpendicular crossing lines illustrate the direction of MR slices, oblique coronal and oblique transaxial.
 Right: Transaxial histological macro-section of the middle third of the SI joint. Ventral sacroiliac ligament (VSIL), Cartilaginous and ligamentous joint space (CJ and DJ). The ventral and dorsal transition zones (VT and DT) can only be assessed by oblique transaxial MR images. Iliac and sacral bone (I and S).

Literature

1. Puhakka KB, Melsen F, Jurik AG, Boel LW, Vesterby A, Egund N. MR imaging of the normal sacroiliac joint with correlation to histology. *Skeletal Radiol.* 2003; 33:15–28
2. Egund N, Jurik AG. Anatomy and histology of the sacroiliac joints. *Semin Musculoskelet Radiol.* 2014;18:332-340.
3. Sieper J, Rudwaleit M, Baraliakos X, Brandt J, Braun J, Burgos-Vargas R, et al. The Assessment of SpondyloArthritis international Society (ASAS) handbook: a guide to assess spondyloarthritis. *Ann Rheum Dis.* 2009;68(Suppl 2):ii1–i44.
4. Puhakka KB, Jurik AG, Egund N et al. Imaging of sacroiliitis in early seronegative spondylarthropathy. Assessment of abnormalities by MR in comparison with radiography and CT. *Acta Radiol* 2003;44(2):218-29.
5. Madsen KB, Egund N, Jurik AG. Grading of inflammatory disease activity in the sacroiliac joints with magnetic resonance imaging: comparison between short-tau inversion recovery and gadolinium contrast-enhanced sequences. *J Rheumatol.* 2010 Feb;37(2):293-400.
6. Gong Y, Zheng N, Chen Su-B et al. Ten years' experience with needle biopsy in the early diagnosis of sacroiliitis. *Arthritis Rheumatism* 2012;64 (5):1399–1406 .
7. Mandl P, Navarro-Compán V, Terslev L, Aegerter P, van der Heijde D, D'Agostino MA, et al. EULAR recommendations for the use of imaging in the diagnosis and management of spondyloarthritis in clinical practice. *Ann Rheum Dis.* 2015 Apr 2. pii: annrheumdis-2014-206971. doi: 10.1136/annrheumdis-2014-206971. [Epubaheadofprint] Review].

#4 - 11:00 h

Short summary: Innervation of the SIJ – are we sure it's mainly from dorsal?

Neuhuber, Winfried, Prof. Dr. med., *Anatomic Institute, FAU, University of Erlangen-Nürnberg, Germany (4)*

- 1969 - 1975 *studies of medicine, University of Vienna, Austria*
- 25/06/1975 *M.D. (Dr. med. univ.)*
- 1975 - 1978 *Lecturer, Anatomy Institute, Univ. of Vienna (Prof. W. Zenker)*
- 1978 - 1979 *Lecturer, Anatomy Institute, Univ. of Zürich, Switzerland (Prof. W. Zenker)*
- 1979 - 1983 *general clinical training in Hamburg (Germany) and Bad Ischl (Austria), general practitioner*
- 1983 - 1992 *Senior lecturer, Anatomy Institute, Univ. of Zürich*
- 1989 *„Habilitation“ (PhD) in Anatomy, Histology and Embryology,*
- *since April 1992 Professor of Anatomy and Chairman, University of Erlangen-Nürnberg, Germany*
- *Membership in Editorial Boards: Histochemistry and Cell Biology*
- *The Anatomical Record, associate editor: ‚Cells, Tissues, Organs‘*

ABSTRACT:

Knowledge of the innervation pattern of the human sacro-iliac joint (SIJ) may help in understanding the pathogenesis of lower back pain. Using gross anatomic and microdissection methods, the area of the SIJ was investigated in 8 embalmed human pelvic specimens (4 male, 4 female). Small nerve branches from dorsal rami S1 to S4 were consistently observed entering the complex of the dorsal sacroiliac ligaments. All branches were histologically confirmed to consist of fascicles containing both large and small myelinated and unmyelinated axons. However, small branches apparently derived from the ventrally located sacral plexus or the obturator nerve and entering the ventral sacroiliac ligaments were confirmed to represent either connective tissue or small blood vessels. In addition, two human fetal SIJ were subject to neurofilament immunohistochemistry. Small axon bundles could be demonstrated in the capsule and ligaments of the SIJ. In conclusion, the innervation of the SIJ derives from dorsal sacral rami S1 to S4. However, this does not preclude innervation of ventral sacroiliac ligaments by branches originating dorsally and coursing cranial or caudal around the joint to a ventral destination.

References:

Grob KR et al., *Z Rheumatol* 54:117-122 (1995); Vleeming A et al., *J Anat* 221:537-567 (2012)

#5 - 11:30 h

SIJ biomechanics – which studies are the most reliable ones (cadaver vs. in vivo vs. finite element models) - or are we all too different? (Böhme)

Böhme, Jörg, PD Dr. med. habil., *Clinic for Orthopedic and Traumatologic Surgery, Spine Center, University Hospital, Leipzig, Germany . Co-author: Ligamentous influence in pelvic load distribution; Description of the iliolumbar ligament for computer-assisted reconstruction; Novel insights into the sacroiliac joint ligaments.*

ABSTRACT:

SIJ biomechanics include the investigation of physiological function, pathological disorders and therapeutical strategies. Results of clinical trials and testings on cadaver pelvises are the current gold standard for some problems. Nevertheless a few questions can not be answered by the standard techniques. Since the early seventies the finite element method is used for prediction of load distribution in mechanical structures. The closer the geometrical and biomechanical properties of the model are to reality, the more reliable the results of simulation may be. New geometrical and biomechanical data of pelvic ligaments and bones improve the quality of computer models and allow a prediction of load distribution of the intact and fractured pelvic ring.

#6 -12:00 h

Diagnostic imaging: X-ray, MRI, CT, Scintigraphy, SPECT-CT – What's the adequate individual choice? (Koga)**Koga, Hiroaki, MD, Department of Orthopedic surgery, Kikuno hospital, Kagoshima, Japan***Executive Vice President, Kikuno Hospital, 1995 – 2000: Instructor of Department of Orthopedic Surgery, Kagoshima Graduate School of Medical and Dental Sciences; 2001 – 2013: Director of Orthopedic Surgery Imakiire General Hospital, Kagoshima Japan; 2005 – 2013: Clinical Assistant Professor of Department of Orthopedic Surgery, Kagoshima Graduate School of Medical and Dental Sciences, board member of the 'Japanese Sacroiliac Joint Research Group'***ABSTRACT:**

Radiography, computed tomography (CT), and MRI are not helpful for the diagnosis of painful SIJ dysfunction because these modalities typically only show a few abnormal findings. Further, other imaging modalities are not useful for the diagnosis of SIJ dysfunction. Although there are no conclusive tests for the diagnosis of SIJ dysfunction, SIJ blocks are the current gold standard; an analgesic response to a properly performed anesthetic block is the most reliable method of diagnosing SIJ dysfunction.

It is reasonable that the pathology of SIJ dysfunction is derived from sacroiliac joint space. Imaging should be connected directly to the pathogenesis of the disease. We investigated the relationship between the presence of severe SIJ dysfunction confirmed by SIJ block and tracer accumulation of the sacroiliac joint space as shown on SPECT/CT. After the recent developments in combined SPECT and CT imaging, the potential for identifying the exact location of scintigraphic lesions has improved compared to that with SPECT alone. In the present study, we aimed to evaluate the diagnostic value of SPECT/CT for SIJ dysfunction.

Thirty-two patients with severe SIJ dysfunction unresponsive to 1 year of conservative treatment who had a score of 4 points on a 10-cm visual analog scale (VAS) underwent SPECT/CT in Imakiire General Hospital. In the present SPECT/CT study, SUV was used for the quantitative analysis of regional activity concentration of the injected tracer. The mean duration of follow-up was 15.3 months. All 32 (10 men and 22 women; mean age, 49.4 years) patients with severe SIJ dysfunction showed tracer accumulation, with a mean SUV of 4.7. Twenty-nine patients had bilateral SIJ dysfunction including 19 patients with lateralized symptom intensity (Group A): 11 patients had right-sided symptom dominance and 8 patients had left-sided symptom dominance, and 10 patients had no lateralized symptom intensity (Group B). Three patients had unilateral SIJ dysfunction (Group C), and all these three patients exhibited left-sided symptoms. All 19 patients with lateralized symptom intensity (Group A) showed a higher SUV on the symptom-dominant side than on the non-dominant side. The mean SUV of the dominant side was 5.3, which was significantly higher than that of the non-dominant side. However, in the 10 patients without lateralized symptom intensity (Group B), the difference in the SUV between the sides was 0.6. The mean difference in the SUV between the two sides in Group B was 0.22, which was significantly lower than the mean difference in the SUV between the 2 sides in Group A ($P = 0.0006$). In the three patients with unilateral SIJ dysfunction (Group C), the affected side had tracer accumulation, with a mean SUV of 3.6; no tracer accumulation was noted in the non-affected side.

Patients were initially treated with drug therapy using nonsteroidal anti-inflammatory drugs (NSAIDs), opioids, steroids, and narcotics in addition to other conservative treatment options.

In cases that did not respond to conservative treatment in the present study, surgery for SIJ fixation was performed. At the final follow-up, 22 patients had been treated with oral NSAIDs, opioids, and steroids (Group D), whereas five patients were treated with narcotics due to resistance to oral medications (Group E). Five patients who were resistant to conservative treatment underwent surgery for SIJ fixation (Group F). The mean SUV in Groups D, E, and F were 4.4, 5.4, and 7.4, respectively.

Although there were no statistically significant differences, Group F had higher SUV than Group E, and Group E had higher SUV than Group D. Thus, higher levels of tracer accumulation tended to indicate the need for more advanced treatment (in the cases of bilateral SIJ dysfunction, higher SUV was used).

Our findings suggest that the use of SPECT/CT adds value in detecting patients with SIJ dysfunction, who are resistant to conservative treatment. We observed a tendency for a higher tracer accumulation in patients with greater symptom severity who also required more advanced treatment.

Thus, we believe that SPECT/CT might be a suitable supplementary diagnostic modality for SIJ dysfunction, and may be useful for predicting the prognosis of this condition.

#7 - 14:00 h

SIJ Arthritis – an obliged group of patients to receive arthrodesis, even at times of biologicals? (Sieper)

Prof. Dr. med. Joachim Sieper, Sieper, Joachim, Prof. Dr. med, Head of Rheumatology, Charité - University Hospital, Berlin, Germany

Member of the Drug Commission of the German Medical Association

Med. Klinik I; Gastroenterologie/Infektiologie/Rheumatologie, Klinikum Benjamin Franklin der Charité, Leiter der Rheumatologie

Ausgewählte Aufgaben und Funktionen

Directing chair of the Regional Rheuma Center Berlin since 1991

Core areas

Clinically: Clinic, diagnosis and therapy of spondylarthropathy; Clinic, diagnosis and therapy of rheumatoid arthritis; kollagenosis

Research: T-cell immunology in pathogenesis of spondylarthropathy; early diagnosis and new therapies for spondylarthropathy

ABSTRACT:

The term axial spondyloarthritis (axSpA) covers patients with typical sacroiliitis on x-rays (called radiographic axSpA = ankylosing spondylitis) and patients in the earlier phase of the disease without structural damage visible on x-rays but with inflammatory sacroiliitis most often detectable on MRI (termed non-radiographic axSpA). AxSpA starts typically with inflammation in the SI-joints causing clinical symptoms such as low back pain and morning stiffness in the lower back/pelvis. However, the longterm consequences of this chronic inflammatory disease is rather determined by the involvement of the spine which can potentially result in an ankylosis of the spine. Other possible extraspinal clinical manifestations are peripheral arthritis, enthesitis or uveitis.

Early anti-inflammatory treatment is crucial to achieve a good clinical response and to prevent longterm bone damage. In contrast to other chronic inflammatory rheumatic diseases the treatment options are limited, but effective. Pharmaceutical treatment is started with NSAIDs which is then followed by a TNF-blocker if NSAID therapy is not sufficient. Most recently, it was also shown that another biologic drug targeting the cytokine interleukin 17 seems to be similarly effective compared to TNF-blocker. However, this drug has not yet been approved for the treatment of axSpA by the regulatory authorities and its exact role in the treatment algorithm of axSpA has still to be determined. Pharmaceutical treatment has always to be accompanied by exercise therapy.

The role of local treatment of axSpA is less well defined, but local glucocorticoid injections in inflamed areas of the SI-joints and or spine have successfully been used. The role of surgery, especially for the SI-joints, is quite limited for this systemic chronic inflammatory rheumatic disease. This is different for other causes of inflammatory sacroiliitis, such as bacterial sacroiliitis.

#8 - 14:30 h

Surgery or not? - How to clinically examine the SIJ? (Stuge)

Stuge, Britt PT, PhD, Senior Researcher, Div. for Neuroscience and Musculoskeletal Medicine, University Hospital, Oslo, Norway

B. Stuge has practised as a physiotherapist since 1982, completing an MSc in 2001 and a PhD in 2005. Britt has worked in clinical practice with women experiencing pregnancy-related pelvic girdle pain for nearly 20 years. Amongst other published works she is co-author of the European guidelines for the diagnosis and treatment of pelvic girdle pain (2008) having been a member of the European Commission group exploring the subject.

ABSTRACT:

Unfortunately there is no single universally accepted diagnostic method for sacroiliac (SIJ) pain. Clinical examination of patients with pain in the SIJ area should however include a thorough pain history and clinical tests. Even though there are many tests devised to provide information about the SIJ, only pain provocation SIJ tests have been shown to have satisfactory inter-examiner reliability and validity with respect to a meaningful reference standard. The aim of a provocation test is to apply stress to the SIJ to determine if the usual pain is produced or aggravated. As there is not one single SIJ test with high sensitivity and specificity, a multi-test regimen of three or more positive tests is recommended. SIJ provocation tests may however provoke false positive pain in the presence of discogenic pain. A recommended method to rule out discogenic pain is to examine for centralisation of pain with repeated movement testing.

SIJ injection is considered the best test currently available for diagnosing SIJ pain, so it is the adopted gold standard. However, factors such as a placebo effect, referred pain, central sensitization, expectation bias, symptomatic blockade, systemic absorption, and psychosocial issues can affect the sensitivity and specificity of diagnostic blocks. To improve diagnostic precision, the use of the double-block standard is advocated. This method repeats the positive block with a different substance to improve sensitivity of the test. Controlled blocks are the reference standard recommended by the International Association for the Study of Pain and the International Society for the Study of Lumbar Spine for diagnosing SIJ pain, and almost complete ablation of pain following confirmed intra-articular injection is regarded as the standard required to consider the response to anesthetic block positive.

Intra-articular injection as a diagnostic reference standard has however limitations as probably only the internal structures of the SIJ are anaesthetized by the procedure. Extra-articular SIJ ligamentous pain will then not be identified. Superficial sacroiliac joint structures, such as the long dorsal sacroiliac ligament, are a potential source of pain. It has been found that experimental pain induced in the long dorsal sacroiliac ligament in healthy subjects gives positive pain provocation tests and has a negative influence on muscle activity with excessive muscle stabilization, similar to that which is seen in patients with pelvic girdle pain (PGP).

According to European guidelines for low back pain, PGP is a subgroup of low back pain. PGP is defined as pain experienced between the posterior iliac crest and the gluteal fold, particularly in the vicinity of the SIJ. PGP disorders may be represented by a number of sub-groups with different underlying pain mechanisms. There is some evidence that PGP is related to an altered pelvic mechanism and/or motor control. An impaired load transfer during activities may result in overload of the ligaments of the pelvis and hence have an influence on PGP. Also, the sacrospinous ligament has been found to be a possible source of pain in PGP.

Surgery or not? Only when the SIJ is proven to be the source of pain and nothing else helps, which means, if the patient is sufficiently clinically diagnosed and has been through an optimal conservative treatment procedure, surgery should be considered. Surgery is recommended to be within a research protocol and proper post-operative rehabilitation is recommended.

References

1. Aldabe D, Milosavljevic S, Bussey MD. Is pregnancy related pelvic girdle pain associated with altered kinematic, kinetic and motor control of the pelvis? A systematic review. *Eur.Spine J.* 2012;21:1777-87.
2. Eichenseer PH, Sybert DR, Cotton JR. A finite element analysis of sacroiliac joint ligaments in response to different loading conditions. *Spine (Phila Pa 1976.)* 2011;36:E1446-E1452.
3. Kokmeyer DJ, van der Wurff P, Aufdemkampe G et al. The reliability of multitest regimens with sacroiliac pain provocation tests. *Journal of Manipulative and Physiological Therapeutics* 2002;25:42-8.
4. Laslett M, Aprill CN, McDonald B et al. Diagnosis of sacroiliac joint pain: validity of individual provocation tests and composites of tests. *Man.Ther.* 2005;10:207-18.
5. Laslett M, Williams M. The reliability of selected pain provocation tests for sacroiliac joint pathology. *Spine* 1994;19:1243-9.
6. Laslett M, Young SB, Aprill CN et al. Diagnosing painful sacroiliac joints: A validity study of a McKenzie evaluation and sacroiliac provocation tests. *Australian Journal of Physiotherapy* 2003;49:89-97.
7. Palsson TS, Graven-Nielsen T. Experimental pelvic pain facilitates pain provocation tests and causes regional hyperalgesia. *Pain* 2012;153:2233-40.
8. Palsson TS, Hirata RP, Graven-Nielsen T. Experimental Pelvic Pain Impairs the Performance During the Active Straight Leg Raise Test and Causes Excessive Muscle Stabilization. *Clin.J.Pain* 2014.
9. Snijders CJ, Vleeming A, Stoeckart R. Transfer of Lumbosacral Load to Iliac Bones and Legs .1. Biomechanics of Self-Bracing of the Sacroiliac Joints and Its Significance for Treatment and Exercise. *Clinical Biomechanics* 1993;8:285-94.
10. Torstensson T, Lindgren A, Kristiansson P. Corticosteroid injection treatment to the ischiadic spine reduced pain in women with long-lasting sacral low back pain with onset during pregnancy: a randomized, double blind, controlled trial. *Spine (Phila Pa 1976.)* 2009;34:2254-8.
11. Torstensson T, Lindgren A, Kristiansson P. Improved function in women with persistent pregnancy-related pelvic pain after a single corticosteroid injection to the ischiadic spine: a randomized double-blind controlled trial. *Physiother.Theory.Pract.* 2013;29:371-8.
12. van der Wurff P, Buijs EJ, Groen GJ. A multitest regimen of pain provocation tests as an aid to reduce unnecessary minimally invasive sacroiliac joint procedures. *Archives of Physical Medicine and Rehabilitation* 2006;87:10-4.
13. Vleeming A, Albert HB, Ostgaard HC et al. European guidelines for the diagnosis and treatment of pelvic girdle pain. *European Spine Journal* 2008;17:794-819.

#9 - 15:00 h

Which SIJ injection is better to diagnose most SIJ-related pain correctly, intra-articular or peri-articular? What response do we require? (Kurosawa)

Kurosawa, Daisuke, MD, Department of Orthopedic surgery, Low back pain and Sacroiliac joint center, JCHO Sendai hospital, Sendai, Japan (9)

Daisuke Kurosawa, M.D. 2004: Graduated from Yamagata University School of Medicine. 2009–Present: JCHO Sendai Hospital Dept. of Orthopaedic Surgery/ Low Back Pain and Sacroiliac Joint Center. Board member of the Japanese Sacroiliac Joint Research Association. License: Japanese Board of Orthopedic Surgery. Instructor of Japanese Medical Society of Arthrokinematic approach.

ABSTRACT:

Two types of SIJ injection The intra-articular SIJ injection has been widely used to identify the origin of SIJ-related pain. However, recent European guidelines¹ do not recommend the intra-articular injection because it cannot assess pain originating from the peri-articular ligamentous region. We demonstrated that the peri-articular injection was more effective than the intra-articular injection for SIJ-related pain relief². The intra-articular injection was effective for only 36% of the patients. The others additionally required the peri-articular injection for SIJ-related pain relief.

Method of injection 1. Intra-articular: We use a new technique³. With the patient in the prone position and the fluoroscopic tube angled 20-25° cephalad, the posterior aspect of the inferior SIJ is clearly depicted caudally. When a 23-gauge needle pricks the joint capsule, contrast medium is injected gently. After contrast medium outlines the joint, about 2ml of 2% lidocaine is injected. 2. Peri-articular: The patient lies in a prone oblique position with the involved side down on a fluoroscopic table. The posterior area of SIJ is divided into four sections and a 23-gauge needle is inserted into each section. A mixture of 2% lidocaine and contrast medium (mixture ratio 1:1) is injected into the section where the needle irritation can reproduce the pain with the patient stating "that is my pain". It should be confirmed that the solution does not spread outside of the posterior SIJ ligamentous region^{2,4}.

Response In order to identify the origin of the pain, we have to check whether the usual pain is reproducible by needle irritation or provocation by the pressure of injection and then relieved by infiltration of a local anesthetic. SIJ-related pain can be more easily reproduced by the peri-articular method rather than the intra-articular method. We demonstrated the relation between the

referred pain area and SIJ posterior sections⁴. Patients are diagnosed as having SIJ-related pain definitively if their pain decreases >70% after the SIJ injection using the pain relief scale⁵.

Conclusion We believe that the peri-articular region is more often responsible for the SIJ-related pain rather than the intra-articular region. The peri-articular injection should be performed first for the patients with SIJ-related pain.

References:

1. *Vleeming A (Eur Spine J. 2008),*
2. *Murakami E (J Orthop Sci. 2007),*
3. *Dussault RG (Radiology. 2000),*
4. *Kurosawa D (Eur Spine J. 2015),*
5. *Lee JJ (Pain Physician. 2015)*

#10 - 16:00 h

Denervation – but do it right!

Shannon L. Roberts, Robert S. Burnham, Trevor J. G. Robinson, Anne M. Agur, Eldon Y. Loh

Roberts, Shannon, PhD candidate, Division of Anatomy, Dept. of Surgery, University Toronto, Canada

Shannon Roberts is a PhD candidate in the Division of Anatomy, Department of Surgery, University of Toronto. She has published 3 peer-reviewed papers and presented 31 abstracts at national and international anatomical and clinical meetings. Shannon Roberts is a member of a collaborative research team that includes Physical Medicine and Rehabilitation physicians, Dr. Eldon Loh and Dr. Robert Burnham, and clinical anatomist, Dr. Anne Agur. She is currently investigating the innervation of the sacro-iliac joint and the relationships of the nerves to ultrasound landmarks. Based on this work, a novel ultrasound-guided radiofrequency ablation technique for the treatment of sacro-iliac joint complex pain was proposed. A cadaveric study assessing the accuracy of needle placement and a clinical study evaluating the effectiveness of the proposed ultrasound-guided sacro-iliac joint radiofrequency ablation technique are currently underway.

ABSTRACT:

INTRODUCTION. Fluoroscopically guided radiofrequency ablation (RFA) techniques used to treat sacro-iliac joint (SIJ) complex pain are technically difficult, as identification of bony landmarks can be challenging. SIJ RFA has had limited success when compared to other regions of the spine. Detailed knowledge of the course of the lateral branches of the posterior sacral rami, relative to bony landmarks visible using ultrasound (US), would provide an anatomical basis for the development of an US-guided SIJ RFA technique. The purpose of this study was to: (1) document in 3D the course of the lateral branches of the posterior rami of L5-S4 that innervate the posterior aspect of the SIJ, relative to bony landmarks visible using US; and (2) propose an US-guided SIJ RFA technique based on innervation patterns and surrounding bony landmarks.

METHODS. Twenty-five cadaveric hemipelves (20 formalin embalmed/5 unembalmed), with a mean age of 75.2 ± 13.1 years, were used in this study. The lateral branches of the posterior rami of L5-S4 were exposed and each nerve branch that innervated the posterior aspect of the SIJ was digitized, along with the posterior surfaces of the sacrum, ilium, L5 vertebra and interosseous sacro-iliac ligament, using a Microscribe™ 3DX Digitizer. To construct a 3D model of each specimen as in situ, the digitized data were reconstructed with Autodesk® Maya® 2013. The course of each lateral branch that innervated the posterior aspect of the SIJ was defined and the innervation patterns compared between specimens. The distances of the nerves relative to bony landmarks visible using US were quantified. Based on the findings, an US-guided SIJ RFA technique was proposed.

RESULTS. The posterior sacral network (PSN), a fine nerve plexus, was found to innervate the posterior aspect of the SIJ in all specimens. The PSN received contributions from the lateral branches of the posterior rami of S1 and S2 in 100% of specimens, S3 in 88%, S4 in 4%, and L5 in 8%. The first, second and third transverse sacral tubercles (TSTs) of the lateral sacral crest were found to be consistent bony landmarks for the PSN. In 22/25 specimens, all branches of the PSN coursed over the lateral sacral crest between TST1 and TST3. An S1 branch was found to course superior to TST1 in two specimens and an S4 branch inferior to TST3 in one specimen. Both branches innervated the SIJ directly. Based on the distribution of the PSN relative to TST1-TST3, an US-guided lateral sacral crest RFA technique was proposed. This technique involves creating a strip lesion along the lateral sacral crest from TST1 to TST3, which would, in most cases, capture close to 100% of the PSN.

CONCLUSIONS. Based on the results of this anatomical study, the proposed US-guided SIJ RFA technique could capture all branches of the PSN that innervate the posterior aspect of the SIJ. Since this technique uses US guidance and bony landmarks that border the PSN, it may be more reproducible than current RFA techniques and would eliminate the risk of radiation from fluoroscopy. A cadaveric study of US-guided needle placement using this technique is currently underway. Future clinical studies are required to investigate outcomes.

#11 - 16:30 h

SIJ braces – what's the philosophy and do they really help? (Harms)

Harms, Jürgen, Prof. Dr. med., Spinal Surgery, Ethianum Klinik, Heidelberg, Germany (11)

Prof. Dr. med. Jürgen Harms is an internationally renowned specialist in the field of spinal surgery. He has conducted more than 10,000 spinal surgeries and is thus one of the most experienced experts on the spine worldwide. He has prepared innovative surgical techniques in scoliosis surgery, tumor surgery, transoral surgery, transforaminal lumbar interbody fusion (TLIF) or the dorsal fixation of the atlantoaxial complex which are in the meantime being practiced throughout the world. This experience led him to advocate to avoid unnecessary surgery. Prof. Harms has published several articles about SIJ biomechanics and physical treatment.

#12 - 17:00 h - Round-table:

Diagnostic algorithm for SIJ pathologies: can we establish a gold standard or shall we just continue to try what we are used to? (Fuchs, All)

ABSTRACT:

Sacroiliac joint disease is a quite frequent cause of chronic low back pain and dysfunction. An increasing number of minimal invasive implants to fuse the painful SIJ are introduced to the market. Spectacular reports on SIJ fusion attract spinal-, orthopedic- and neurosurgeons to start surgery for the SIJ. My experience as a surgical tutor over the past 6 years and as the director of a multicenter study revealed that the vast majority of surgeons are not really familiar with a thorough diagnosis and SIJ treatment options - either non invasive or invasive. It must be imperatively stated that surgery of the SIJ should be the ultimate treatment option when everything else has failed. Assertions that surgical SIJ treatment is economically in favor against sufficient conservative therapy should be doubted and revision cost should be considered if surgeons are misguided to perform uncontrolled interventions.

An algorithm for assessing SIJ dysfunction as the cause of low back pain is imperative to provide clinicians with a useful tool in decision making. Nevertheless it must be pointed out that the diagnosis of SIJ related pain is still a challenge.



#13 - 08:00 h

What are the different SIJ- and leg pain generators and what is the physicians' view on the appropriate therapy? (Donner)

Dr Donner is a American Board of Orthopedic Surgeons & American Board of Spinal Surgery certified orthopedic spinal surgeon who has over 20 years experience diagnosing and surgically treating patients with SI joint pain and dysfunction and has presented scientific papers at multiple international meetings on SI joint related topics during his career including the outcomes of SI joint fusion surgeries.

Dr Donner completed his orthopedic surgery training at Temple University Hospital and a spinal surgery fellowship at the Hospital of the University of Pennsylvania, Temple University Hospital and Shriners' Hospital in Philadelphia Pennsylvania, USA and is a member of multiple medical societies including the American Academy of Orthopedic Surgeons, North American Spine Society, International Spinal Intervention Society. Dr Donner recently authored a chapter in the book, Surgery for the Painful, Dysfunctional Sacroiliac Joint, focusing on the minimally invasive, posterior inferior approach.

ABSTRACT:

Lumbosacral pain, with or without leg pain, is one of the most common complaints a spinal specialist is consulted to diagnose and provide treatment. The etiology of the painful condition may be due to pathologies of multiple anatomic structures which often times are difficult to discern or accurately confirm. A logical approach to identifying and treating these painful conditions will be outlined based on both personal clinical experience and the best available medical literature.

#14 - 08:25 h

There's more than the SIJ: Considerations for when to operate on the sacroiliac joint(s) and the lumbar spine at the same setting (Eden)

Dr. Sonia V. Eden is Assistant Professor at Western Michigan School of Medicine, Neurosurgery, Co-author of the book 'Surgery for the Painful, Dysfunctional Sacroiliac Joint'.

ABSTRACT:

Introduction: Prior studies have suggested that many patients who present with failed back syndrome may indeed suffer from sacroiliac joint (SIJ) dysfunction. The purpose of this study is to report a retrospective series of patients undergoing treatment for potential pain generators in the SIJ and the lumbar spine simultaneously.

Methods: This is a retrospective analysis of a series of patients who were treated at the Borgess Medical Center in Kalamazoo, MI between 2005 and 2010.

Results: 35 patients were treated with lumbar fusions and SIJ fusions at the same setting. The average follow-up was 41 months. There was an 83% satisfaction rate. There were no deaths, infections, neurovascular injuries, or lasting co-morbidities. 83% of the patients would have the surgery again for the same result.

Conclusion: Lumbosacral spine pathology and sacroiliac joint pathology can be addressed in the same setting with decreases in pain, low reoperation rates, and high satisfaction scores at long-term follow-up. Determining the pain generators and addressing all of them is paramount and may help reduce the 'failed back' patient population.

#15 - 08:50 h

Neurovascular Consequences and Comorbidities (Stark)

ABSTRACT:

New understanding of the surrounding anatomy of the painful sacroiliac joint. Neural and vascular anatomic considerations will dictate the proper surgical approach

The SIJ stands as the direct mechanical connection of axial and extremity anatomy. The complex situation, which includes absolute and cyclic loading results more than extreme joint reaction force: deformity also results, and this deformity is enmeshed in what are arguably the most vulnerable and most unyielding neurovascular-orthopedic relationships.

The spinal canal, the Iliac-superior gluteal arterial complex, the lumbar roots, are intimately related to the SIJ on every side. Surgical treatment of the SIJ must not only avoid and protect this complex structure but also provide for the correction of the SIJ's complex secondary neurovascular effects.

#16 - 09:15 h

It's not as simple as it seems: Complications of sacroiliac fusion and salvage considerations (Graham Smith)

Graham Smith, Arnold, MD, FRCS, FACS, Jacksonville, FL 32256 (16, 17)

Dr. Arnold Graham Smith studied Medicine at King's College, London University, UK, and later studied Orthopaedic Rehabilitation at Rancho Los Amigos, in Los Angeles where he worked with paraplegics and wheelchair people in the SCI unit. Interdisciplinary treatment philosophy has stayed with him ever since and he still relies on the expertise of a treatment team for the best outcomes. He is a member of the Board of Directors of the ABSS (American Board of Spine Surgery), where he was chairman of the examination committee. He believes that spine surgery is now so complex that it should only be performed by surgeons with special training. Just as orthopaedic and neurological surgeons require Board certification, so spine surgeons can now become Board Certified. Dr. Graham Smith is a member of the North American Spine Society and a Founder Member of ISIS.

ABSTRACT:

Getting the diagnosis right, by history, examination and testing is important, and it often reveals dual pathology. There is no single magic diagnostic test for this condition. Injection testing requires an experienced doctor committed to diagnosis. Coronal CT scans may reveal anomalous sacral anatomy, important for surgical planning. The surgeon should become familiar with all the implants available, and understand the shortcomings and dangers of each procedure. Complications of infection, wound breakdown and venous thrombosis may occur with any operation. Non-union is more common in smokers and those who take anti-inflammatory medication. An early postoperative CT scan reassures the surgeon that no harm has been done, and it is also an educational tool to learn how to do the operation better. It may be that the implant could have been longer. It may be that the de-cortication could have been more aggressive.

Minimally invasive procedures often use a lateral approach, placing nerve roots at risk as well as the superior gluteal artery. The anterior approach is extensive and provides poor access to the SI joint. Fusing this joint is difficult and the best results are achieved with rigid fixation, adequate calcium intake, biologic chemical assistance with healing and patience to let it heal by the sufferer. Everyone is different and some people heal quicker than others. Delay PT until the joint has healed. This is NOT an operation to repeat. Failure to resolve pain may need additional grafting, additional fixation or careful discovery of another pain generator.

In the UK, the NHS has mandated Patient Reported Outcome Measures (PROMs). We have written our own for the sacroiliac joint. Pain is 1-10:

1. What is your overall level of pain now in your entire body?
2. What is your SIJ level of pain now? (Compare with pre-op level of pain).
3. What was your worst level of SIJ pain in the last week?
4. Has the operation helped you?
5. Would you go through the operation again if necessary?
6. Are you aware of any other painful place?
7. Is there anything else you want to tell me?

The Oswestry and SF36 scoring systems are about function, not pain. In our experience, when the pain has gone, function will return.

For more in-depth information and articles go to www.spine-doc.com.



#17 - 10:00 h – Pro/Contra:

SIJ arthrodesis – when and why do we use anterior, posterior or lateral techniques – or do ‘many ways lead to Roma’? And what about preserving motion? (Chair: Graham Smith, Kibsgård)

- **Anterior: Murakami**
- **Posterior: Stark**
- **Lateral: Eden**
- **Motion preservation: Donner, Seeber**

Murakami, Eiichi, MD, Department of Orthopedic surgery, Low back pain and Sacroiliac joint center, JCHO Hospital, Sendai, Japan

1981: Graduated from Tohoku University School of Medicine. Chief of Low Back Pain and Sacroiliac Joint Center in JCHO Sendai Hospital. Representative Director of the Japanese Sacroiliac Joint Research Association

Anterior arthrodesis of sacroiliac joint for severe sacroiliac joint pain: minimum 5-year follow-up study in 45 patients.

To patients with severe sacroiliac joint (SIJ) pain who show a little response to conservative therapies, the SIJ arthrodesis may have a possibility to relieve the pain.

We performed the anterior SIJ arthrodesis to 45 patients with severe SIJ pain, failed to conservative therapy more than six months from 2002 to 2015. Among those 45 patients, we evaluated the outcome of the patients at least a 5-year follow-up after the SIJ arthrodesis.

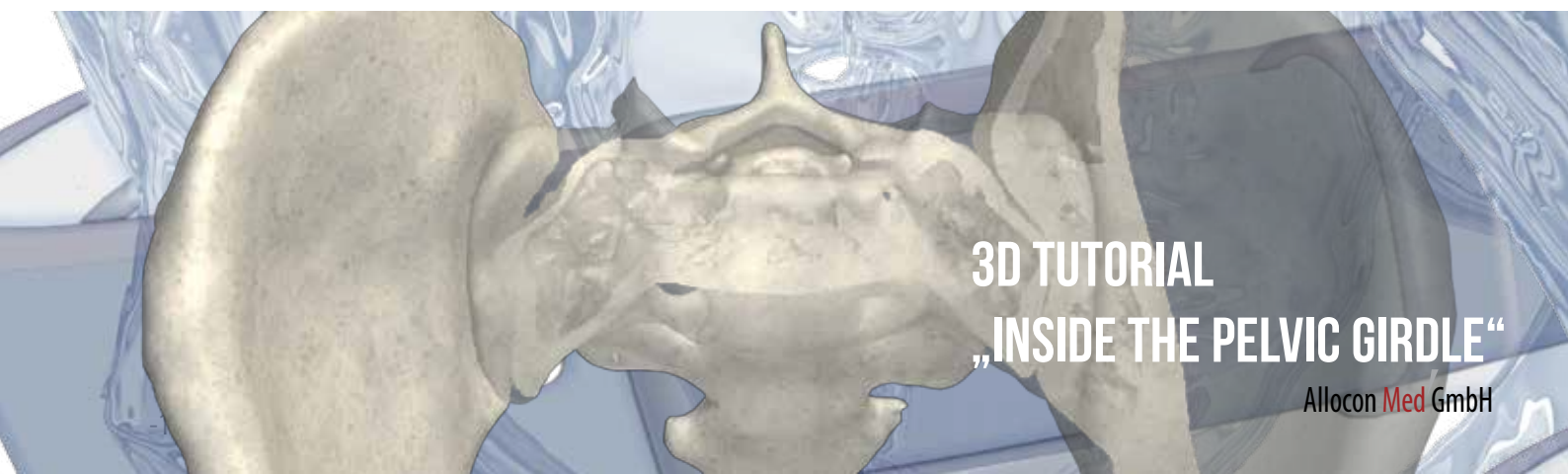
Surgical technique: For the exposure of the SIJ, in the early period of this study, we used an anterior approach by separating iliac muscle from iliac bone, while recently, we changed an extra-peritoneal, pararectal approach through rectus abdominal muscle. Then, the joint was curetted and fixed with plate and screws after bone graft.

Materials: Twenty three patients with a minimum 5-year follow-up averaged 113 months (61-157) were the subject of the present study, including 9 males and 14 females, mean age 48.6 years (24-86) at surgery. The SIJ arthrodesis included single anterior approach in 17 patients and combined anterior and posterior approaches in 4 patients, and anterior approach with pelvic ring fusions in 2.

Outcomes: Operation time was averaged 205 minutes (150-327). All cases were confirmed union of the joint by CT. The surgical outcome was excellent in 5 patients, good in 12, fair in 4, poor in 2 according to MacNab Criteria. Pain relief scale was averaged 3.5 (1-8). Visual analogue scale was improved from 83.6 (65-95) to 28.5 (5-76), Roland-Morris disability questionnaire was improved from 21.1 (19-23) to 9.5 (1-22). Sitting time and walking time was improved from 5.4 minutes (0-20) to 96.7 (20-180), from 7.9 minutes (0-30) to 69.3 (5-240), respectively.

Complications: There were 3 patients whose screw was dislocated, and 7 patients whose lateral cutaneous nerve was injured.

Conclusions: Anterior SIJ arthrodesis has an advantage to curette directly and graft bone into the wide area of the SIJ, which should result in good bony union although it is an invasive surgery with some technical problems.



3D TUTORIAL
„INSIDE THE PELVIC GIRDLE“

Allocon Med GmbH

#18 - 11:00 h

Clinical studies on SIJ fusion – how true can we get? (Kibsgård)

Kibsgård, Thomas, VMD, Orthopedic Department, University Hospital, Oslo, Norway (17, 18)

Author: ,Pelvic joint fusions in patients with chronic pelvic girdle pain: a 23-year follow-up'. He will present a review on available studies on SIJ surgical treatment.

ABSTRACT:

In the history many attempts have been done to treat sacroiliac joint pain, and fusion to the sacroiliac joint have had various popularity. During the last years multiple companies have developed a solution to surgically treat sacroiliac joint pain. If we look at the papers that have been published the last 4 - 5 years many of the authors have close connection to the industry, and all papers report positive outcome. Further, many claim that a randomized control trial is unethical due to lack of standardized conservative treatment option and the superiority of these new implants.

Is it possible to study this surgical procedure in the same way that we study other orthopedic conditions? The answer to this question can easily be answered: Yes. But there are strengths and limitations in all study designs and a combination of different designs can be used in order to get closer to the truth. Two types of studies are most often used to test new procedures, randomized control trials and observational studies. With the knowledge of the limitation and strengths of these different types of study designs we may draw conclusions about the effectiveness of sacroiliac joint fusion.

#19 - 11:30 h - Round-table (Proposals are available for download)

What preoperative data and scores do we need? How do we avoid comparing apples with pears in the future? (Stuge, Kibsgård, All)

Proposed study design:

- International prospective multicenter observation single arm study Options (preferable), 2 arms RCT surgical/non surgical or 2 arms RCT surgical method 1/ surgical method 2
- Inclusion/exclusion criteria
- Indications
- Laboratory diagnostics
- Imaging
- Postoperative Treatment
- Scores (**the questionnaires of standard scores need to be adapted to SIJ specifications**):
 - ODI
 - McGill
 - SF12
 - MVAS
 - Roland-Morris
 - patient satisfaction
 - depression status
 - individual score (NEW: „That's MY problem")
 - pain diagram

ABSTRACT: What do we demand from a control group and how do we validate the quality? (Stuge)

Different types of control groups exist; no-treatment controls, placebo controls and comparative treatment controls. Each of these groups has advantages and disadvantages (e.g. blinding, treatment expectations, drop-out) with respect to a determination of clinical outcome¹⁵. Optimal conservative (non-surgical) treatment should be a pre-requisite before even considering surgery for sacroiliac joint (SIJ) pain. In the case of comparing surgery with conservative treatment both treatment arms should be of best possible quality to make a fair comparison. There is a lack of evidence based treatment for SIJ pain, however some evidence exists for low back pain and pelvic girdle pain (PGP) involving the SIJ.

Exercise therapy is a common treatment prescribed and core stabilization exercises have grown in popularity⁷. Two different core stabilization strategies exist, with controversy about which is the optimal strategy^{2,3}. The motor control exercise approach emphasizes specific exercises for local muscles, whereas the general exercise approach focuses exercises on global muscles^{8,9}. It has been suggested that therapeutic exercises purporting to restore motor control of specific selected local muscles are unnecessary¹. On the other hand, generic stabilizing exercises do not address the individual motor control deficits identified in patients⁴ and there is a risk of increased co-contraction of trunk stabilizing muscles during tasks that provoke pain with an inability to relax muscles^{4,13}. A recent systematic review also showed strong evidence that stabilisation exercises are not more effective than any other form of active exercise in the long term¹⁰. Consequently, interventions should focus less on specific stabilizing muscles and more on daily activities and optimal dynamic control of movements, as inherent underlying maladaptive movements might act as potential ongoing peripheral nociception rather than a strategy to avoid pain⁴.

One systematic review has investigated the effectiveness of physical therapy for the treatment of PGP postpartum⁵. The only randomized controlled study showing significant and long-lasting effects included a homogeneous group of patients based on clinical examination and criteria for PGP^{12,14}. The treatment program studied was individualized and focused on exercises for motor control and stability of the pelvic girdle. The main focus of the exercises was to improve coordination of the local and overall muscle system, especially addressing the dynamic control of a neutral position of the lumbopelvis, subsequently to develop strength and endurance to manage the physical demands facing each individual. Additionally, essential points addressed were SIJ restrictions, posture, breathing, and cognitive behavioural perspectives. Cognitive aspects were an important part of the intervention, in addition to the exercises. The women were ordered to perform their 30-60 minutes exercise program three days a week and they adhered closely to this regime for 20 weeks. A qualitative study elucidating this treatment program found that by being active agents in managing their PGP the women learned to set themselves proximal goals, perceived hope and self-efficacy¹¹.

Adhering to an exercise regime is a challenge⁶ and it is important that exercises should not provoke pain during or after exercising. It might be that group exercise classes, even supervised, with a focus on cardiovascular endurance training and strength training, are not addressing the pain provoking factors in individual patient. To secure and validate the quality of treatment, physiotherapists ought to have evidence based skills, listen attentively, individualize and evaluate treatment¹¹.

Reference list

1. Brumitt J, Matheson JW, Meira EP. Core stabilization exercise prescription, part 2: a systematic review of motor control and general (global) exercise rehabilitation approaches for patients with low back pain. *Sports Health* 2013;5:510-3.
2. Brumitt J, Matheson JW, Meira EP. Core stabilization exercise prescription, part 1: current concepts in assessment and intervention. *Sports Health* 2013;5:504-9.
3. Bruno P. The use of „stabilization exercises“ to affect neuromuscular control in the lumbopelvic region: a narrative review. *J.Can.Chiropr.Assoc.* 2014;58:119-30.
4. Dankaerts W, O'Sullivan P. The validity of O'Sullivan's classification system (CS) for a sub-group of NS-CLBP with motor control impairment (MCI): overview of a series of studies and review of the literature. *Man.Ther.* 2011;16:9-14.
5. Ferreira CW, Albuquerque-Sendin F. Effectiveness of physical therapy for pregnancy-related low back and/or pelvic pain after delivery: A systematic review. *Physiother.Theory.Pract.* 2012.
6. Haakstad LA, Bo K. Effect of a regular exercise programme on pelvic girdle and low back pain in previously inactive pregnant women: A randomized controlled trial. *J.Rehabil.Med.* 2014.
7. Liddle SD, David BG, Gracey JH. Physiotherapists' use of advice and exercise for the management of chronic low back pain: a national survey. *Man.Ther.* 2009;14:189-96.
8. McGill S. *Low Back Disorders: Evidence-Based Prevention and Rehabilitation*. 2nd ed. Champaign, IL: Human Kinetics, 2007.
9. Richardson C, Hodges P, Hides J. *Therapeutic exercise for lumbopelvic stabilization. A motor control approach for the treatment and prevention of low back pain*. 2nd ed. Edinburgh: Churchill Livingstone, 2004.
10. Smith BE, Littlewood C, May S. An update of stabilisation exercises for low back pain: a systematic review with meta-analysis. *BMC.Musculoskelet.Disord.* 2014;15:416.
11. Stuge B, Bergland A. Evidence and individualization: Important elements in treatment for women with postpartum pelvic girdle pain. *Physiother Theory.Pract.* 2011.
12. Stuge B, Lærum E, Kirkesola G et al. The efficacy of a treatment program focusing on specific stabilizing exercises for pelvic girdle pain after pregnancy. A randomized controlled trial. *Spine* 2004;29:351-9.
13. Stuge B, Saetre K, Ingeborg HB. The automatic pelvic floor muscle response to the active straight leg raise in cases with pelvic girdle pain and matched controls. *Man.Ther.* 2013.
14. Stuge B, Veierød MB, Lærum E et al. The efficacy of a treatment program focusing on specific stabilizing exercises for pelvic girdle pain after pregnancy. A Two-Year Follow-up of a Randomized Clinical Trial. *Spine* 2004;29:E197-E203.
15. Vernon H, Humphreys BK, Hagino C. The outcome of control groups in clinical trials of conservative treatments for chronic mechanical neck pain: a systematic review. *BMC.Musculoskelet.Disord.* 2006;7:58.

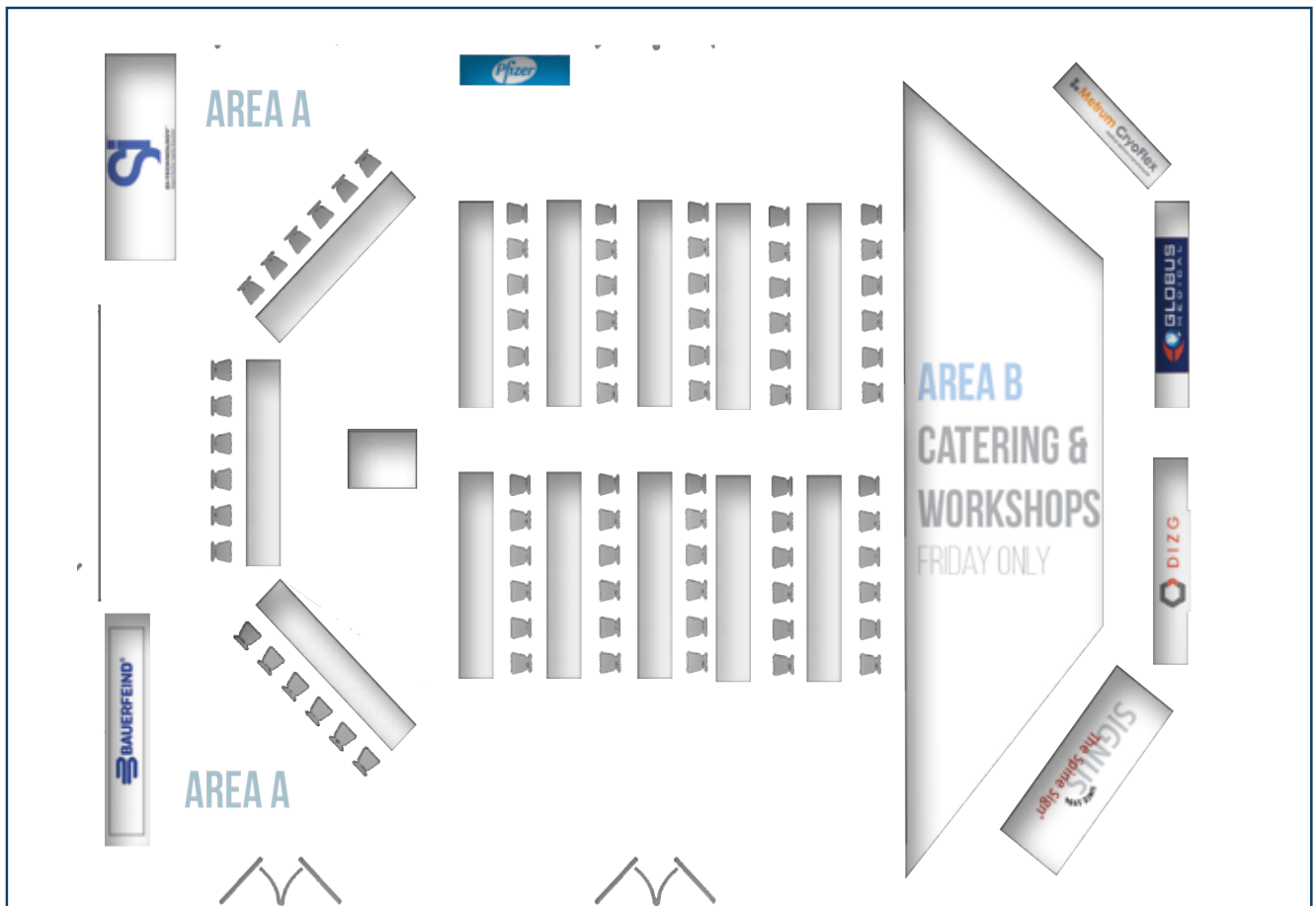
Time Table ICSJS 2015					
Ref.	Morning Sessions	Afternoon Sessions	Ref.	Morning Sessions	Special Sessions
	08:00 h Registration	12:30 h - 14:00 h Industry Exhibition and Lunch-Workshop		08:00 h - 09:40 h SJ Surgery	
1	09:00 h - 10:30 h SJ Introduction <i>History of SJ Fusion</i> <i>SJ-Case Register</i> <i>Anatomy</i>	14:00 h - 15:30 h Indication <i>Pathology</i> <i>Physical Tests</i> <i>Infiltration</i>	7	<i>Pain generators</i> <i>When to operate</i> <i>Who to operate</i> <i>Complications</i>	1 13:00 h - 13:45 h SIMEG Members Meeting
2			8		
3			9		2 14:00 h - 15:00 h Hands on Workshop
				Coffee Break	3 15:00 h - 16:00 h Optional: Speakers Summary
4	11:00 h - 12:30 h Inside the Sacroiliac Joint			10:00 h - 11:00 h Pro/Contra <i>Surgical techniques</i>	
5	<i>Innervation</i> <i>Biomechanics</i> <i>Radiology</i>	16:00 h - 17:00 h Non Surgical Treatment <i>Denervation</i> <i>Manual Therapy</i>	10		
6			11	11:00 h - 11:30 h	
				11:30 h - 12:00 h <i>Designing SJ studies</i>	
		17:00 h - 18:00 h Round Table <i>Diagnosis</i>	12	12:00 h - 12:30 h	
	Lunch			12:30 h - 13:00 h	
				13:00 h END	

INDUSTRIAL WORKSHOPS AND EXHIBITION

Latest SIJ surgical technologies will be presented at the Lunch-Workshop. Exhibition is located inside the auditorium.

Exhibitors/Sponsors

1. Bauerfeind AG, 07937 Zeulenroda-Triebes/GER
www.bauerfeind.com
2. German Institute for Cell and Tissue Replacement, a not-for profit Inc., 12555 Berlin/GER, www.dizg.de
3. Ilion Medical, Inc., Minneapolis, MN 55402 / USA
www.ilionmedical.com
4. Globus Medical UK Ltd., SHEFFIELD S35 2PH / UK
www.globusmedical.eu
5. Metrum Cryoflex, 05-092 Łomianki n/Warsaw Poland, EU, www.metrum.com.pl/en
6. Pfizer Pharma GmbH, 10922 Berlin/GER
www.pfizer.de
7. SIGNUS Medizintechnik GmbH, 63755 Alzenau/ Germany, www.signus.com
8. SI-Technology, LLC, 80524 Fort Collins, Co, USA
www.si-technology.co



VENUE

Dorint Hotel Hamburg-Eppendorf

Martinistr. 72 / 20251 Hamburg /Germany

T +49 40 570 150 0 / F +49 40 570 150 100

www.dorint.com/hamburg



Regardless of whether yours is a private or a business trip to Hamburg, you are sure to find the ideal location of our hotel most welcome indeed: close to the city centre and in perfect proximity to the exhibition centre, the congress centre, the airport and the A 7 motorway. The Dorint Hotel Hamburg-Eppendorf is also a direct neighbour of the university clinic, a hospital which enjoys a good worldwide reputation. There are even two glass walkways directly linking the hotel to the specialist clinic and the Hamburg Centre for Anaesthesiology. You would like to set out from the hotel to visit the sights of the Hamburg Harbour and the Inner Alster? No problem! There are public transport stops right on the doorstep, so there are no limits whatsoever to your exploratory outings into town.

FEES AND SERVICE


Fees

Full conference	500 €
One day ticket Friday	300 €
One day ticket Saturday	200 €
Members*	250 €
<i>*confirmed members only. A non confirmed application for membership does not justify reduced fee.</i>	
Physiotherapists/non surgeons	250 €
Conference Dinner:	60 €

include

- › Conference participation
- › Physical examination hands-on workshop
- › Coffee breaks
- › Lunch on Friday
- › Abstract download
- › Download of conference audio/video protocol

ORGANIZING HOST



Sacroiliac Medical Expert
Group e.V.

www.si-meg.com

T +49 2196 709013

F +49 2196 732 536

info@si-meg.com

www.si-meg.com

Organizing committee:

- › Michael Dierks, Medical Device Consultant
- › Dr. med. Volker Fuchs, President SIMEG e.V.

Supported by:

Conventus Congressmanagement &
Marketing GmbH • 07745 Jena
www.conventus.de

Grafic design and artwork: Allocon Med GmbH

SIMEG is a „Medical Experts Association for Research into Diseases of the Sacroiliac Joints and their Treatment“ of casualty surgeons, orthopaedic surgeons, neurosurgeons, neurologists, physiotherapists together with scientists and other persons, who work surgically and conservatively in the treatment of the sacroiliac joints and of the pelvic girdle in hospital, practice and research. The association is independant. Registered at the Federal Court of Cologne VR 18315. Tax no./AZ 230/5724/3251 K zst, FA Leverkusen/Germany, acknowledged as non profit organization acc. to  60a Abs. 1 AO



M.E.G.